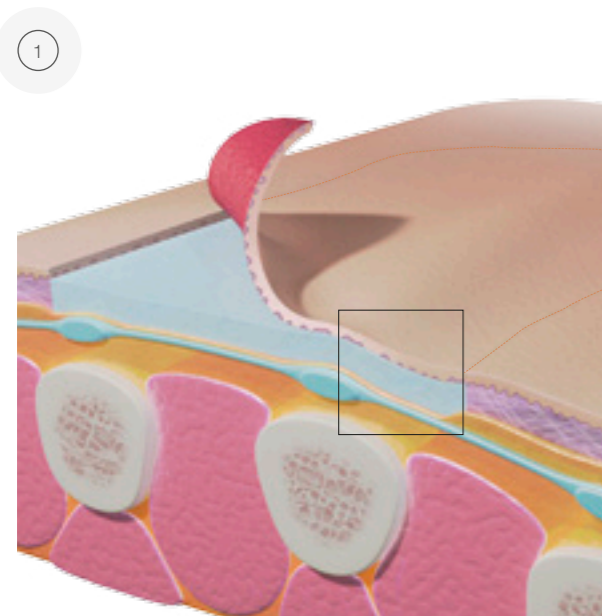


De belangrijkste succesfactor

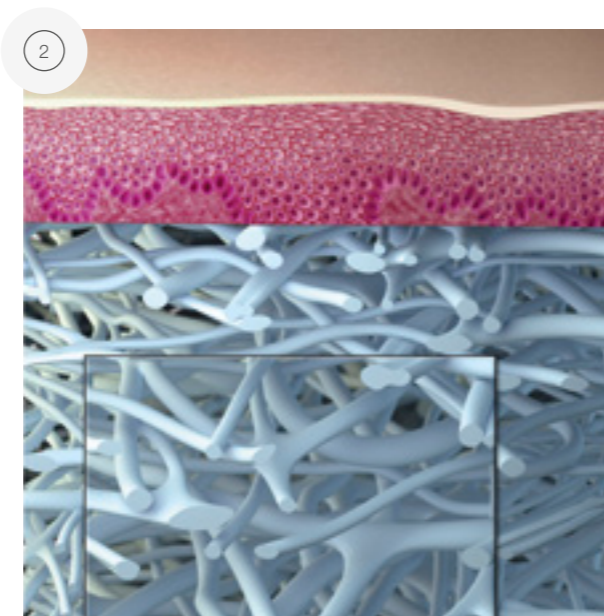
De belangrijkste succesfactor van MatriDerm® Dermal Matrix is onze Advanced CryoSafe™-methode die de natuurlijke biologische eigenschappen van de collageen-elastinematrix behoudt.

Werkingsmechanisme MatriDerm® Dermal Matrix

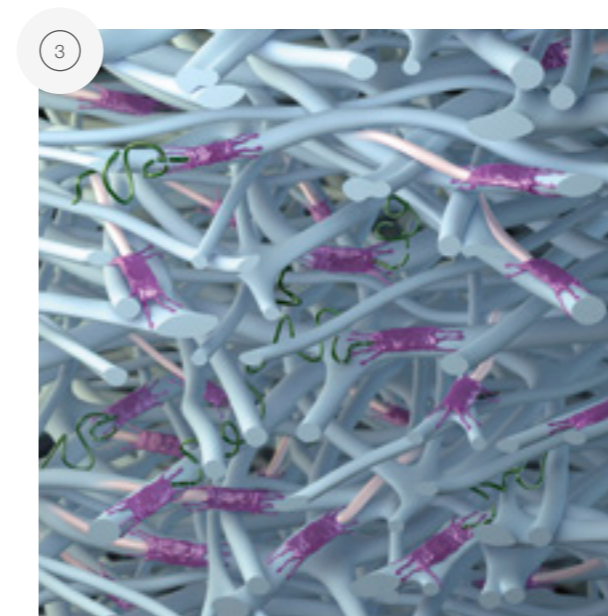
MatriDerm® Dermal Matrix is een unieke collageen-elastinematrix, die dient als een bouwwerk bij huidvervanging.



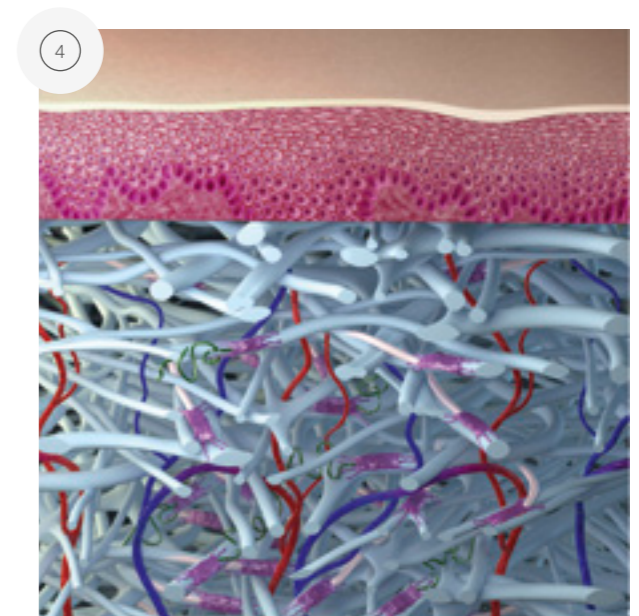
vfiivfiivfi((fi)fiififi)v v(fi
D]fiufiuoD]fivfi
Pfi ofivfi filufififivo]d]lvfi]v
(



D]fiufiuoD]fififivvo]ilfi
]fi]ufiv]vofiooPfi fivrfio]vfiu]u
fiou]P]fifivPfi ofi]fiPfi vfi]vPfi
fiPfiullfio]ilfi v uu




&]ofivfi vPfi ofi]fivo]ilfi
ooPfi fivrfio]vfi rfi vPfi vfi vfi
Pfi fifi fiPfi vfi]vPfi v]vPfi fivfi rfi
fiu] . 8, 10, 11



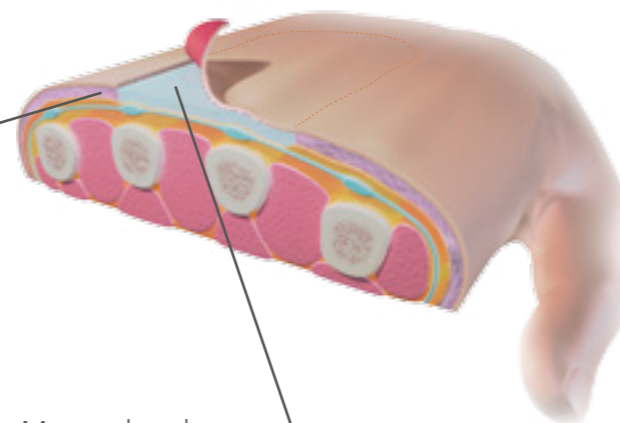
sfififivfi rfi vP]Pfi vfi fivfi v]vPv
u]fi]fiPfi vfi fivfi vfi
]uo]fivovfi o]d]lvfi
l]v(1, 5, 6, 7, 9, 14

Hoe MatriDerm® Dermal Matrix het verschil maakt

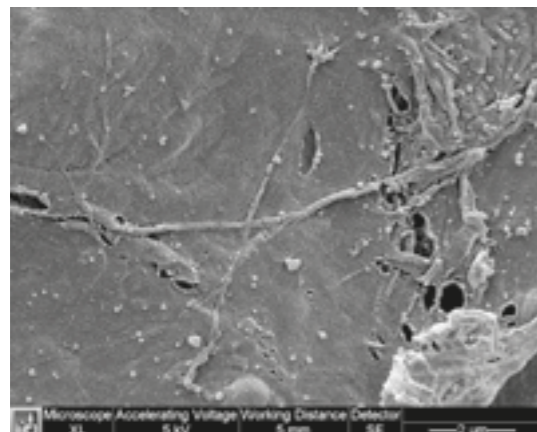
MatriDerm® Dermal Matrix is een unieke collageen-elastinematrix, die dient als een bouwwerk bij huidvervangning.




Menselijke dermis



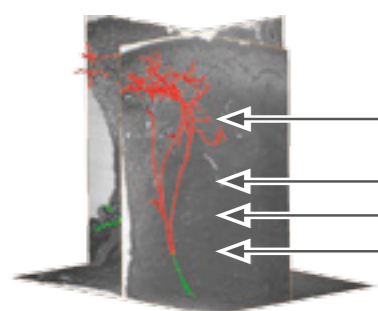
Mensenhand



Andere bewerkte dermale matrix



MatriDerm® Dermal Matrix



STSG*

MatriDerm® Dermal Matrix

Angiogenese dag 15 na implantatie – met dank aan Prof. Kamolz, Oostenrijk

* Split-thickness skin graft

Waarom de bewerking van belang is

Structural integrity and biological activity of the collagen are highly dependent on differences in the manufacturing process.²

The unique MatriDerm® Dermal Matrix manufacturing process (Advanced CryoSafe™ Method) preserves the native collagen triple helical structure as well as the cellular binding sites of its collagen products, which is important for the cellular interaction.²

The MatriDerm® Dermal Matrix Difference

Elastin

- Triggers early vascularization^{3, 4, 5, 19} and may reduce risk of infection (re-vascularization allows for white blood cells to migrate to the site)^{18, 19}
- Significantly improves skin elasticity (compared to split-thickness skin graft alone)^{1, 5, 6, 7, 9}
- Enables early physical therapy and rehabilitation²⁰

Native collagen fibers

- Guided healing to avoid unstructured scar tissue^{8, 10, 11}
- Improved cell migration and reconstruction of new dermis^{10, 11}

One- and Multi-Step Procedure

- Can be used in a One-Step Procedure which saves time and money and enables an early patient mobilization
- If more than one step is needed the wound can already be grafted after 5-12 days

No chemical cross-linking

- Non-release of cell-toxic substances
- Improved cellular growth^{12, 13}

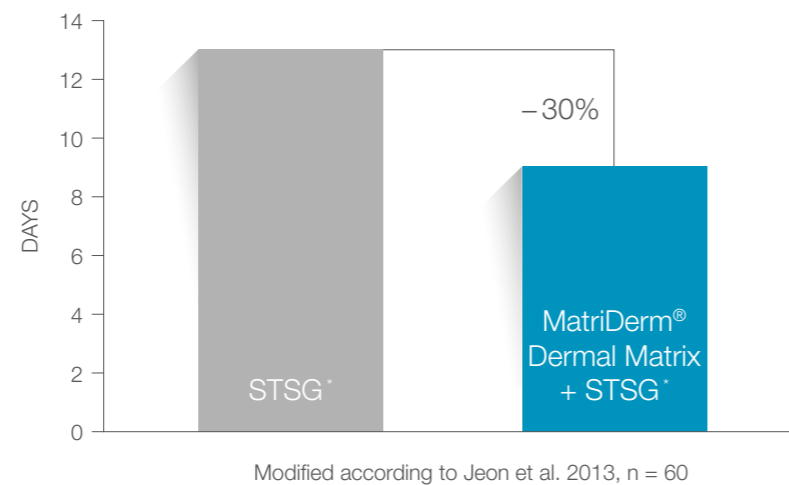
The Clinical Evaluation

Under clinical evaluation MatriDerm® Dermal Matrix has shown to be fast and effective in the management of a range of full-thickness wounds, helping patients back to normal life and reducing the overall cost of care.



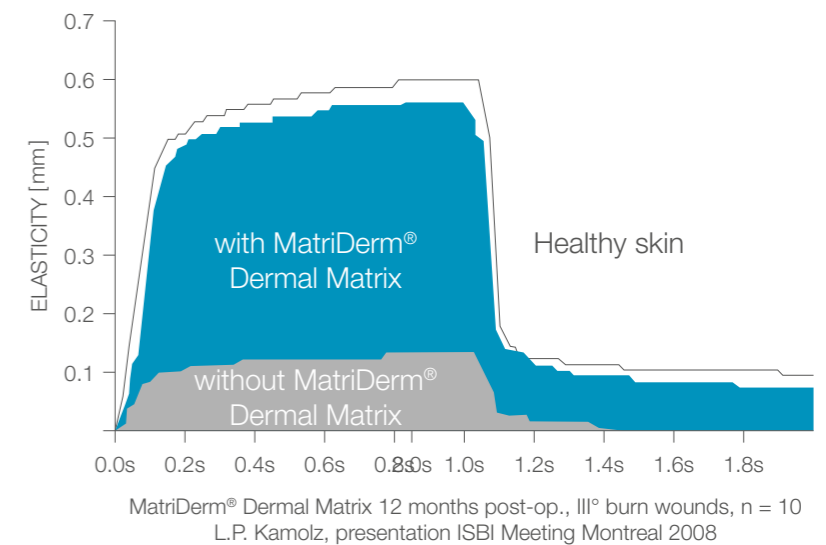
Fast

Shorter healing period with MatriDerm® Dermal Matrix



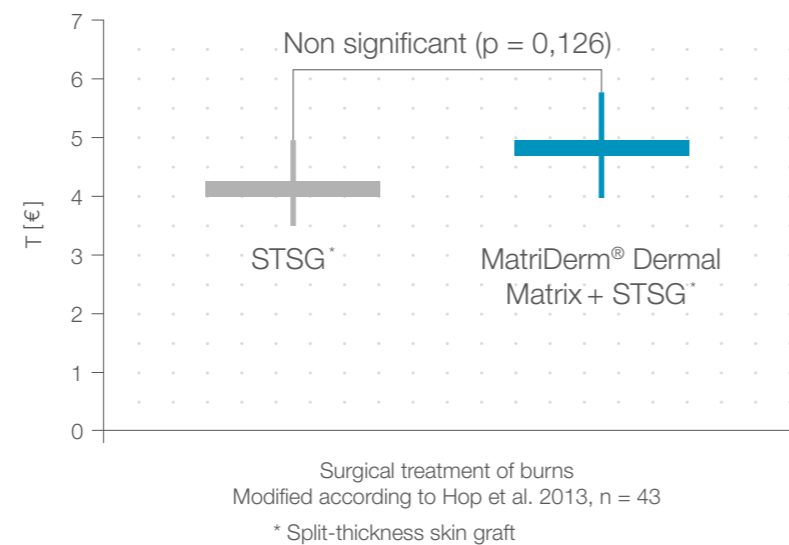
Quality of life

Determination of skin elasticity via Cutometer® measurement



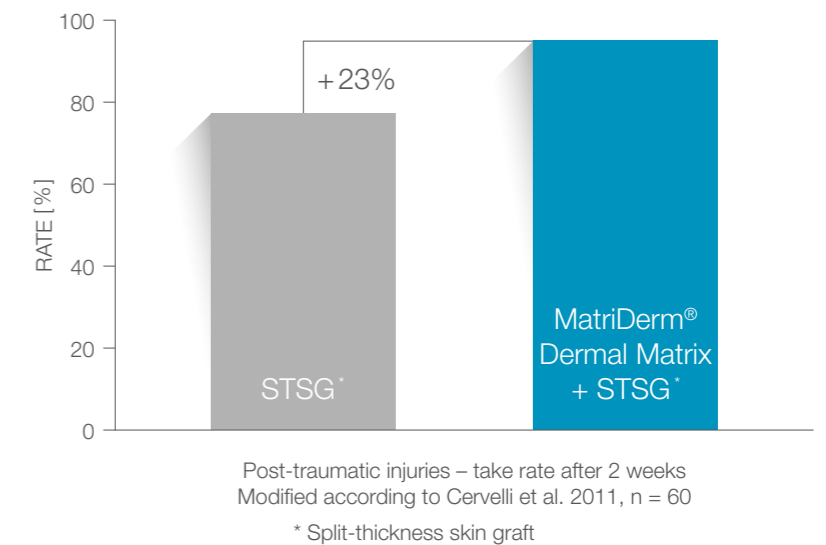
Cost effective

Total surgical treatment costs don't differ significantly from STSG*



Effective

Improved efficacy with MatriDerm® Dermal Matrix

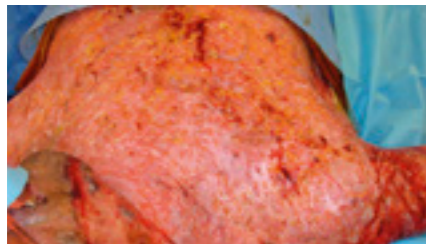

The Clinical Evaluation

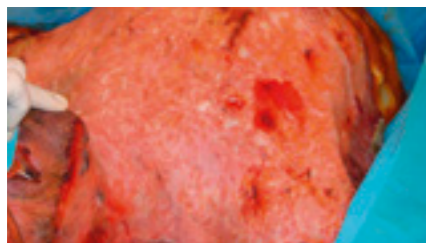The long-lasting effect on scar quality by the use of MatriDerm® Dermal Matrix, even after 12 years, has been shown by Bloemen et. al¹:

- Improved scar parameter
- Improved scar appearance (cosmetic)

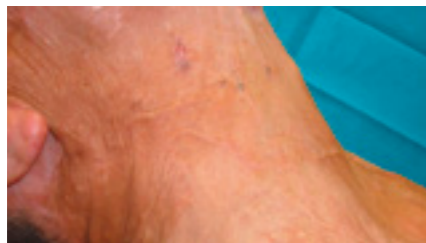Burns*



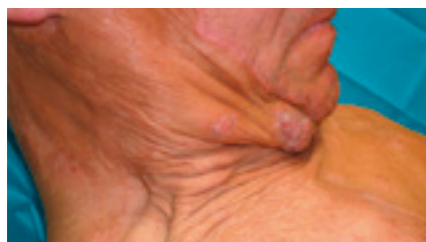Intraoperative



Intraoperative after the application of MatriDerm® Dermal Matrix



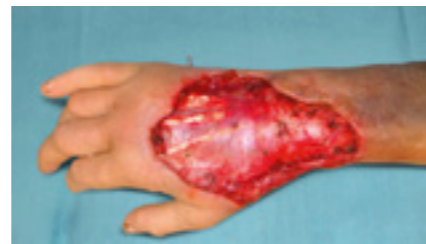3 years postoperative



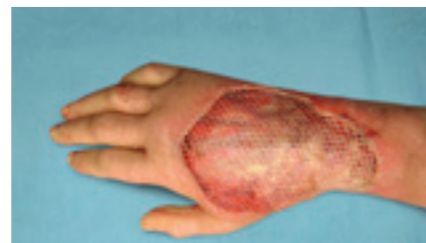3 years postoperative

* Courtesy of E. Dantzer, Toulon, France
 ** Courtesy of U. Hug, MD, Luzern, Switzerland

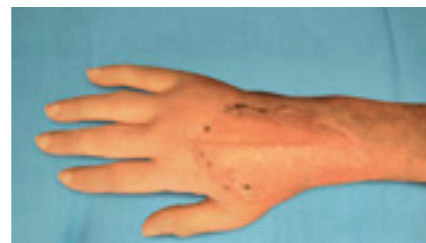Trauma**



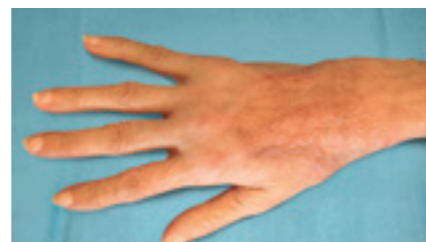Intraoperative after debridement



Intraoperative after the application of MatriDerm® Dermal Matrix and mesh graft

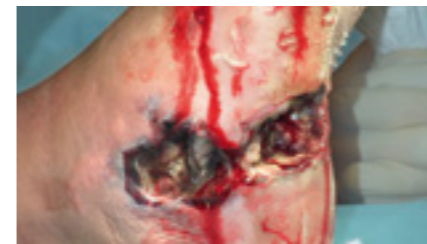

Stable wound closure
3 months postoperative

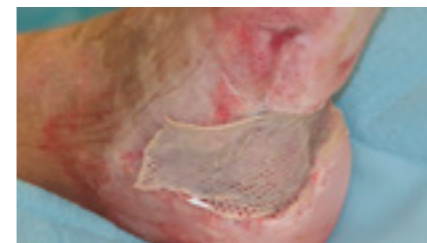

Full extension 2 years postoperative

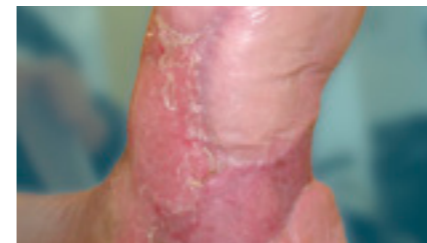Chronic Wound*



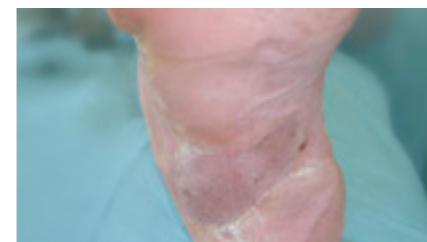Preoperative



Intraoperative after the application of MatriDerm® Dermal Matrix and mesh graft



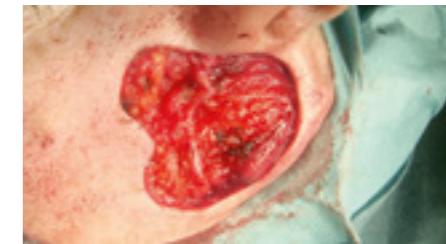3 months postoperative



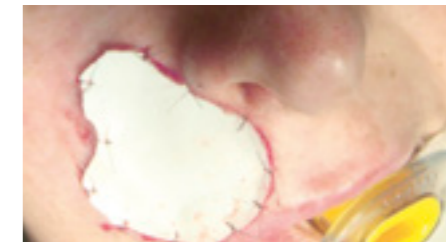
6 months postoperative

* Courtesy of D. Luedi, Langenthal, Switzerland
 ** Courtesy of N. Lilgenau, MD, Vienna, Austria

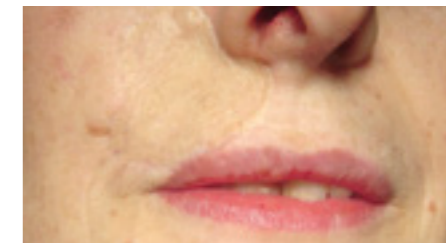
Cancer Excision**



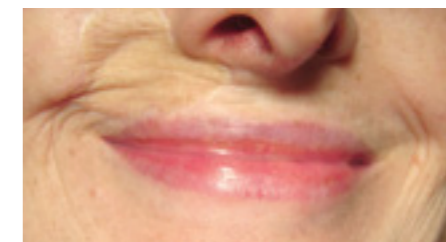After excision



Intraoperative after the dry application of MatriDerm® Dermal Matrix



7 months postoperative



7 months postoperative

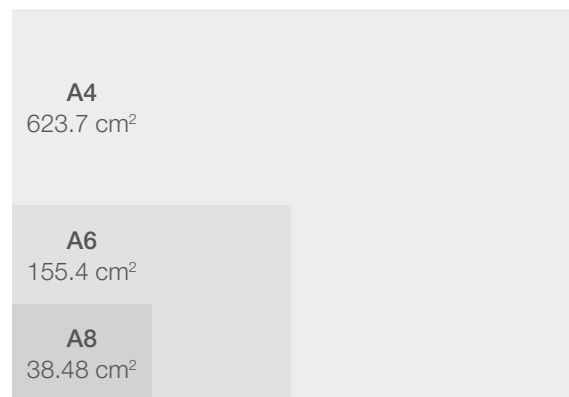
Fast Regeneration Restored Motion

- Fast integration & revascularization^{3, 4, 5, 10, 11}
- Effective closure of full-thickness injuries^{1, 7, 14}
- Cost-effective One-Step Procedure^{15, 16}
- Superior functional & aesthetic outcomes^{1, 7, 17}

	Ref. No.	Size
A4	83500 - 200	210 x 297 x 1 mm
	83400 - 200	210 x 297 x 2 mm
A6	83403 - 200	105 x 148 x 1 mm
	83401 - 200	105 x 148 x 2 mm
A8	83404 - 200	52 x 74 x 1 mm

52 mm

74 mm



MedSkin Solutions Dr. Suwelack AG
Josef-Suwelack-Strasse 2
48727 Billerbeck | Germany

P +49 (0)2543 2182-0

E info@medskin-suwelack.com

W www.medskin-suwelack.com

References

- Bloemen MC et al., *Plast Reconstr Surg*, 2010, 125(5):1450-9
- Böhm S et al., *Materials* 2017; 10(9), 1086
- Geyer et al., *Annals of Anatomy* (2015) 197, 3-10
- Wiedner M et al., *Wound Repair Regen*, 2014, 22(6):749-54
- Daamen WF et al., *Tissue Eng*, 2008, 14(3):349-60
- Haslik W et al., *JPRAS*, 2010, 63(2):360-4
- Ryssel H et al., *Burns*, 2008, 34(1):93-7
- Scanning-Electron-Microscopy-images: © Dr. M. Mörgelin, University Lund, Sweden
- Ryssel H. et al., *Int Wound J.*, 2010, 7(5):385-92
- de Vries H et al., *Wound Repair Regen*, 1994, 2(1):37-47
- de Vries H et al., *Br J Dermatol.*, 1995, 132(5):690-7
- Killat J et al., *Int J Mol Sci.* 2013 Jul 11, 14(7):14460-74
- Wietbrock JO, Dissertation, Ludwigs-Maximilians-Universität München, 2016
- Cervelli V. et al., *Int Wound J* 2011, 8(4):400-5
- Hop M. et al., *Burns* 2013, 40(3):388-96
- Jeon H. et al., *Arch Plast Surg* 2013, 40(4):403-8
- Watta W. et al., *J Sex Med* 2017, 14(10):1277-1284
- Granick, M. S., Teot, L., *informatics Healthcare*, second ed., CRC press 2012
- Frueh F. S. et al., *Journal of Investigative Dermatology* (2017) 137, 217-227
- Haslik et al., *Burns* 2007, 33(3): 364-8